

# Considerations for the management of an edentulous achondroplastic patient: a case report

## Rozważania dotyczące postępowania z bezzębnym pacjentem z achondroplazją: opis przypadku

*Oumaima Tayari<sup>1</sup>, Selma Snène<sup>2</sup>, Nawel Berchèche<sup>2</sup>, Jamila Jaouadi<sup>3</sup>*

<sup>1</sup> Assistant Professor, Department of Prosthodontics, Research Laboratory LR12ES11, Faculty of Dental Medicine of Monastir, University of Monastir, Tunisia

<sup>2</sup> Resident, Department of Prosthodontics, Research Laboratory LR12ES11, Faculty of Dental Medicine of Monastir, University of Monastir, Tunisia

<sup>3</sup> Professor, Department of Prosthodontics, Research Laboratory LR12ES11, Faculty of Dental Medicine of Monastir, University of Monastir, Tunisia

---

### KEY WORDS:

aesthetics, achondroplasia, bone growth, complete removable denture, bearing area

---

---

### HASŁA INDEKSOWE:

estetyka, achondroplazja, wzrost kości, ruchoma proteza całkowita, powierzchnia nośna

---

### Summary

*Achondroplasia is the most common skeletal dysplasia caused by a mutation in the fibroblast growth factor receptor, type 3 gene (FGFR3) and resultant disabling growth and developmental disorders. This complex condition often presents with significant general and specific manifestations. Its oral consequences involve dental formation anomalies and early loss of teeth. Facing a situation of edentulism, careful considerations must be taken into account in prosthetic management depending on the condition of the osteomucosal bearing surfaces and the patient's aesthetic context and preferences, both affected by the specific implications of the syndrome. Accordingly, the treatment protocol must be meticulously tailored to address these distinct considerations, and approaches to treatment must be effectively adjusted to meet the specific needs when taking impressions and managing prosthetic space and aesthetic results by selecting and mounting prosthetic teeth to achieve optimal functional and aesthetic outcomes. This case report describes the comprehensive prosthetic treatment plan developed for an edentulous patient with*

### Streszczenie

*Achondroplazja to najczęstsza dysplazja szkieletu spowodowana mutacją w genie receptora czynnika wzrostu fibroblastów, genu typu 3 (FGFR3) i wynikającymi z niej upośledzającymi zaburzeniami wzrostu i rozwoju. Ten złożony stan często objawia się znaczącymi ogólnymi i specyficznymi objawami. Konsekwencje w jamie ustnej obejmują anomalie zębów i wczesną utratę zębów. W obliczu bezzębia należy wziąć pod uwagę staranne postępowanie w leczeniu protetycznym, w zależności od stanu powierzchni nośnych kostno-szlukówkowych oraz kontekstu estetycznego i preferencji pacjenta, na które wpływają specyficzne implikacje tego zespołu. W związku z tym protokół leczenia musi być szczegółowo dopracowany, aby uwzględnić te odrębne kwestie, a podejścia do leczenia muszą być skutecznie dostosowane, aby spełniać różne potrzeby podczas wykonywania wycisków oraz zarządzania przestrzenią protetyczną i wynikami estetycznymi poprzez wybór i ustawienie zębów protetycznych w celu osiągnięcia optymalnych wyników funkcjonalnych i estetycznych. W tym opisie przypadku opisano kompleksowy plan leczenia protetycznego opracowany dla bezzębnego pacjenta z achondroplazją*

*achondroplasia, underscoring the importance of a personalized, patient-centred approach to effectively restore oral function and aesthetics in the context of this complex skeletal disorder.*

*zją, podkreślając znaczenie zróżnicowanego, skupionego na pacjencie podejścia do skutecznego przywracania funkcji i estetyki jamy ustnej w kontekście tego złożonego zaburzenia szkieletowego.*

## Introduction

Achondroplasia is a nonlethal form of chondrodysplasia whose phenotype is characterized by rhizomatic disproportionate short stature, short hands and lordotic lumbar spine, enlarged head, midface hypoplasia associated with a normal cognitive development.<sup>1,2</sup> It is known to be associated with various oral manifestations such as oligodontia, delayed dental development and eruption, as well as macroglossia and constricted maxilla with a relatively large mandible, resulting in skeletal misalignment and dental malocclusion.<sup>3</sup>

Dentists should be aware of the clinical characteristics of achondroplasia and the complications that may arise when dealing with an edentulous patient. In fact, oral repercussions further complicate the practitioner's approach, since the osteomucosal bearing surfaces are influenced by the bone growth disorder; restoring the patient's aesthetics requires a specific attitude.<sup>4</sup>

The purpose of this case report is to present the prosthetic treatment of an edentulous patient with achondroplasia and to discuss special considerations that should be taken to successfully integrate their removable prostheses and to optimise their oral health and the quality of life.

## Case Report

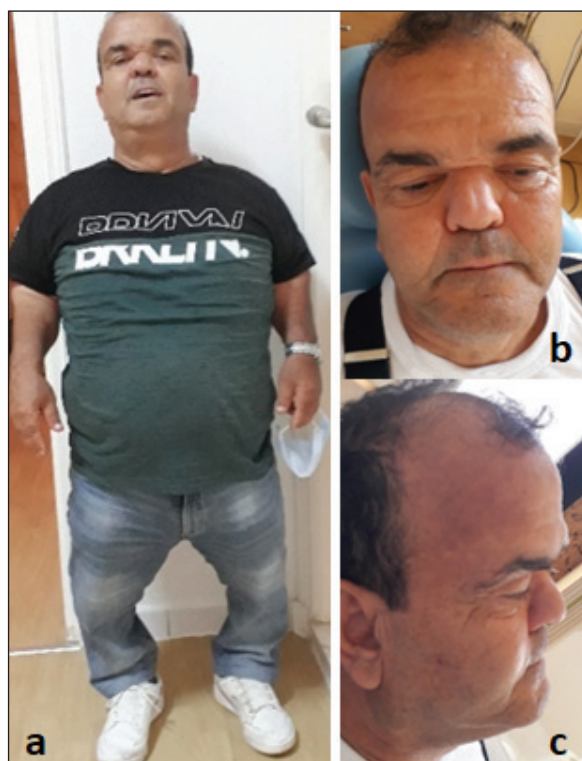A 50-year-old male circus performer, diagnosed with achondroplasia, presented with the chief complaint of the absence of most of his teeth and the pain related to the remaining

ones, which affected his professional situation and the quality of life. The patient had a short stature, measuring 1.28 meters, with rhizomelia and brachydactyly (Fig. 1a).

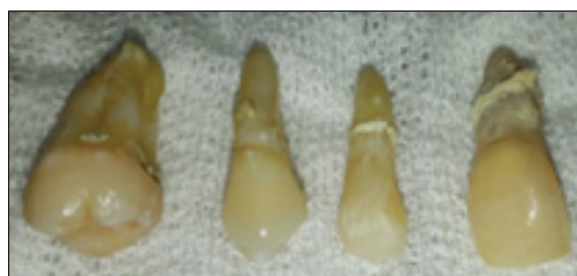During extra-oral examination, it was found that the patient had a large head with a prominent forehead, a depressed saddle-shaped nose, a reduced lower facial height and an overall flat facial profile. (Fig. 1b-1c).

Residual teeth, smaller than normal adult dentition, had to be extracted due to terminal periodontal disease (Fig. 2). Following the post-extraction healing period, intra-oral examination revealed edentulous maxillary and mandibular arches, respectively corresponding to Class II and Class I according to Sanguiolo classification.<sup>4</sup> Maxillary ridge was wide and irregular, with anterior areas of undercuts and a sensitive mobilizable mucosa. The palate was overly deep, with extremely depressible Schroeder zones occupying the palatal side of the posterior ridges (Fig. 3a)<sup>4</sup> Mandibular ridge showed an irregular height that was insufficient posteriorly (Fig. 3b). The patient exhibited macroglossia, with a large tongue invading the entire functional prosthetic space (Fig. 3c).

The overdenture option was not possible due to the lack of strategic teeth to support the attachment system. In addition, due to the patient's professional commitments abroad, the time available for the prosthetic rehabilitation, after discussion, only allowed us to opt for a conventional complete removable prosthesis. The problem of macroglossia was avoided by fitting the teeth within the prosthetic corridor and adjusting the limits and thickness of the



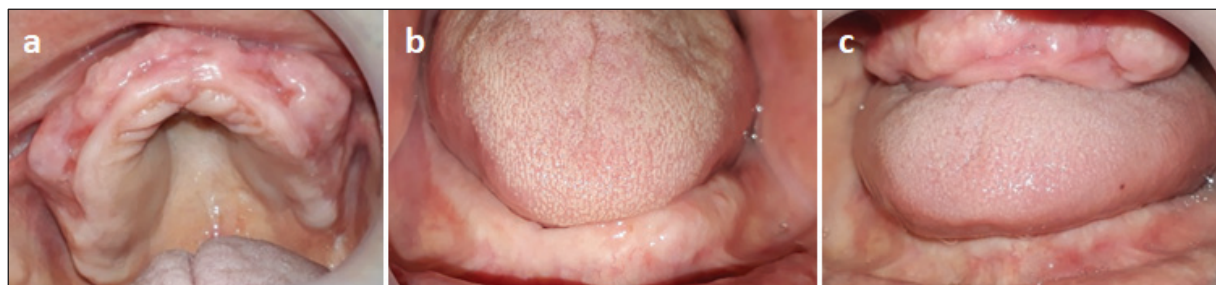**Fig. 1.** Extra-oral examination; a – general posture of the patient, b – front facial view, c – profile facial view.



**Fig. 2.** Residual lost teeth.

and mobilizable areas to allow evacuation of excess impression material, thereby unloading compressed areas. Then, secondary impression was taken with Polysulfides (Fig. 5).

Then occlusion was recorded. Small, triangular-shaped prosthetic teeth were chosen, reflecting the patient’s pre-extraction condition of microdontia and respecting the constrained prosthetic space, then mounted, ensuring proper centric relation and vertical dimension of occlusion while maintaining the balanced occlusion concept and respecting

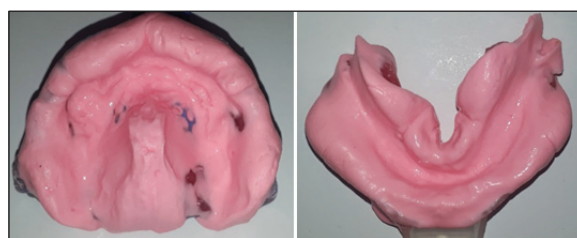


**Fig. 3.** Intra-oral examination; a – maxillary arcade, b – mandibular arcade, c – macroglossia.

prosthetic base in harmony with the lingual and labio-jugal peripheral musculature.

For the maxilla, a conventional dentate impression tray was used to cover the entire ridge extending to the back of the palate. In the mandible, a rectified Schreimakers® impression tray was employed. Primary impressions were taken with Alginate® (Fig. 4).

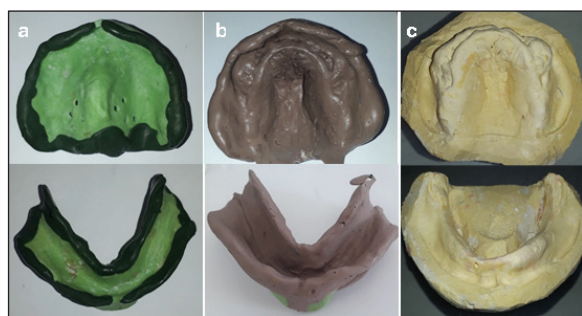
For the secondary impression, the border molding was made with Kerr® green thermoplastic impression compound. After that, perforations were made facing the depressible



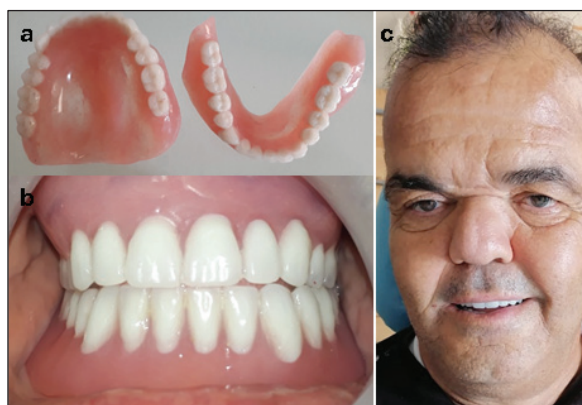**Fig. 4:** Primary impressions with irreversible hydrocolloid.

the prosthetic corridor in relation to the large volume of the tongue. Following tray-in and patient’s approval of the aesthetic result, the





**Fig. 5. Secondary impression; a – border molding, b – impressions, c – master casts.**



**Fig. 6. Finished and polished prostheses; a – transparent areas corresponding to undercuts and depressible zones, b – definitive prostheses in place, c – restored facial appearance.**

teeth-set was sent to the dental laboratory for polymerisation and finishing. It should be noted that cured acrylic resin showed transparent areas corresponding to undercuts and depressible zones (Fig. 6a). Finally, complete removable dentures were placed in to restore aesthetics, masticatory functions and physiological tongue repositioning (Fig. 6b). During follow-ups, a notable improvement in the patient's facial appearance, oral functions and the quality of life was observed (Fig. 6c).

## Discussion

The focus in the prosthetic management of individuals with achondroplasia is on adapting specialized procedures to the anatomical and physiological oral characteristics when complete edentulism occurs.<sup>5</sup>

The gene mutation in achondroplasia leads to abnormal cartilage formation and ossification of the long bones as well as in the base of the skull inducing disproportionately large skull with prominent forehead and mid-face recession with relative prognathism.<sup>1,6</sup> These manifestations lead to exaggerated decrease of the middle and lower facial parts and a hollow face that both accentuate the challenge of aesthetic restoration in an edentulous achondroplastic patient.

Impaired bone growth directly affects the craniofacial skeleton and potentially influences the shape of the edentulous ridge, which can result in atypical ridge patterns and poses significant challenges in fitting dentures, as observed in this case.<sup>6</sup> In fact, the irregular and atypical ridge morphology requires customized impression techniques. This is further complicated by the presence of depressible and mobilizable soft tissue when taking impressions.<sup>5</sup> Two impression techniques were proposed to achieve better support and peripheral seal without displacing the movable tissue of flabby mucosa in achondroplasia.<sup>7</sup> In the first one, the impression custom tray is spaced from the mobilizable mucosa by applying a double layer of wax to the primary cast before applying the resin and then making perforations in the depressible areas before taking the impression as shown in this case.<sup>7</sup> Alternatively, a selective pressure impression is taken with two impression material viscosities and a custom tray with a hole or a “window” over the mobilizable area, according to “the window technique” used with severe and extended flabby areas.<sup>8</sup>

In patients with achondroplasia, the prosthetic space is often limited due to macroglossia and ridge hypertrophy resulting from skeletal deformities.<sup>3,9</sup> In the context of completely edentulous patients, this space must accommodate the dentures and facilitate physiological movement of the mandibular

jaw. For this reason, and to achieve aesthetic satisfaction, selecting prosthetic teeth that integrate harmoniously with the patient's facial architecture is essential. This selection process can be guided by pre-extraction records, such as photographs, dental models, or the retained dentition, as shown in this case. If not, the choice of the shape of anterior teeth is guided by established principles combining the shape of the central incisors and the facial outline, according to Williams' laws of harmony, in addition to considering GPA (gender, personality, age) factors. These elements are crucial in ensuring that prosthetic teeth accurately reflect the individual's identity.<sup>10</sup>

## Conclusion

With achondroplastic patient, a personalized approach emphasizes the need to customize prosthetic dentistry in order to provide a functional and aesthetic solution tailored to patients' general and local characteristics.

## References

1. Zhang X, Jiang S, Zhang R, et al.: Review of published 467 achondroplasia patients: clinical and mutational spectrum. *Orphanet J Rare Dis* 2024; 19(1): 29. doi: 10.1186/s13023-024-03031-1
2. Chawla K, Lamba AK, Faraz F, Tandon S: Achondroplasia and periodontal disease. *J Indian Soc Periodontol* 2012; 16(1): 138-40. doi: 10.4103/0972-124X.94624
3. Swathi KV, Maragathavalli G: Achondroplasia: A form of disproportionate dwarfism – A case report. *Indian J Dent Res* 2020; 31(5): 794-798. doi: 10.4103/ijdr.IJDR\_303\_19
4. Sanguiolo R, Mariani P, Michel J.F, Sanchez M: Les édentations totales bimaxillaires: formes cliniques, thérapeutiques prothétiques. Ed. Juli en PRELAT 1980.
5. Jain S: Prosthodontic rehabilitation of Achondroplastic patient with Resorbed Flabby Ridge. *Clin Dent* 2013; VII, 6.
6. Handa A, Nishimura G, Zhan MX, Bennett DL, El-Khoury GY: A primer on skeletal dysplasias. *Jap J Radiol* 2022; 40(3): 245-261. doi: 10.1007/s11604-021-01206-5
7. Yee A, Meei TI, Ling GC: Managing Fibrous Maxillary Ridge: A Case Series of Impression Techniques. *Prim Dent J* 2023; 12(1): 51-56. doi: 10.1177/20501684231153909.
8. Mizouri A, Tayari O, Mahfoudhi A, Bouguezzi A, Jaouadi J: Preprosthetic Management of "Flabby Ridge" on Edentulous Patient. *Case Rep Dent* 2021; 2021: 6613628. doi: 10.1155/2021/6613628.
9. Sforza E, Margiotta G, Giorgio V, et al.: What to Expect of Feeding Abilities and Nutritional Aspects in Achondroplasia Patients: A Narrative Review. *Genes (Basel)* 2023; 14(1): 199. doi: 10.3390/genes14010199
10. Fajri L, Abdelkoui A, Abdedine A: Approche esthétique en prothèse amovible complète. *Actualités Odonto-Stomatologiques* 2013; 11: 16-26.

Zaakceptowano do druku: 17.11.2024 r.

Adres autorów: Department of Prosthodontics,  
Research Laboratory LR12ES11,  
Faculty of Dental Medicine of Monastir,  
University of Monastir, Monastir, Tunisia.

© Zarząd Główny PTS 2024.