

Biogeneric tool to respect morphology and occlusion for posterior teeth: two clinical cases

Narzędzie biogeneryczne do uwzględniania morfologii i zgryzu zębów bocznych: dwa przypadki kliniczne

Kallala Rim^{1,2,3}, Rihab Dakhli^{1,2}, Yosra Gassara^{1,2}, Amani Adli^{1,2}

¹ University of Monastir, Faculty of Dental Medicine of Monastir, Research Laboratory of Occlusodontics and Ceramic Prosthesis, LR16ES15, Faculty of Dental Medicine, 5000, Monastir, Tunisia.

² Department of Fixed Prosthodontics, Dental Clinic of Monastir, Tunisia
Head: *Belhassen Harzallah*, PHD, Professor

³ Department of Dental Anatomy
Head: *Soumaya Touzi*, PHD, Professor

KEY WORDS:

bonding, inlay, endocrown, esthetics, dental anatomy, onlay

HASŁA INDEKSOWE:

bonding, inlay, endokorona, estetyka, anatomia zębów, onlay

Summary

Regardless of the tooth restoration technique used, the original tooth morphology always serves as the ideal guide for replication. Intact natural tooth morphology is an indisputable reference point in dentistry, playing a crucial role in both form and function, especially for posterior teeth.

Previously, for milled restorations, the occlusal morphology was derived from a library of standard morphologies. However, contemporary dentistry offers the biogeneric tooth model, an innovative tool that ensures respect for both morphology and occlusion in each clinical situation. It utilizes a computer-controlled matching process, referencing the affected tooth to the opposite, adjacent, or contralateral tooth.

This paper aims to highlight the contribution of the biogeneric tool by comparing two distinct clinical scenarios: one with and one without the biogeneric tool.

The first clinical report details an older case of an endocrown restoration using the virtual library of morphologies. The second clinical report details the application of the biogeneric tool and demonstrates the resulting respected

Streszczenie

Niezależnie od zastosowanej techniki odbudowy zęba, pierwotna morfologia zęba zawsze służy jako idealna wskazówka do odwzorowania. Nienaruszona naturalna morfologia zębów jest niekwestionowanym punktem odniesienia w stomatologii, odgrywającym kluczową rolę zarówno pod względem formy, jak i funkcji, szczególnie w przypadku zębów bocznych.

Dawniej, w przypadku uzupełnień frezowanych, morfologię zgryzu ustalano na podstawie biblioteki standardowych morfologii. Jednak współczesna stomatologia oferuje biogeneryczny model zęba, innowacyjne narzędzie, które zapewnia poszanowanie zarówno morfologii, jak i zgryzu w każdej sytuacji klinicznej. Wykorzystuje sterowany komputerowo proces dopasowywania, odnosząc zmieniony chorobowo ząb do zęba przeciwnego, sąsiadującego lub przeciwległego.

Celem tego artykułu jest podkreślenie wkładu narzędzia biogenerycznego poprzez porównanie dwóch różnych scenariuszy klinicznych: jednego z narzędziem biogenerycznym i drugiego bez niego.

morphology. A step-by-step protocol, from design to cementation, is described for both restoration cases.

Pierwszy raport kliniczny szczegółowo opisuje wcześniejszy przypadek odbudowy endokoroną przy użyciu wirtualnej biblioteki morfologii. Drugi raport kliniczny szczegółowo opisuje zastosowanie narzędzia biogenerycznego i przedstawia uzyskane w ten sposób poszanowanie morfologii. W obu przypadkach opisano protokół postępowania krok po kroku, od projektu do cementowania.

Introduction

Regardless of the technique used for tooth restoration, the original tooth morphology is the ideal guide to reproduce and recreate. Intact natural tooth morphology is an indisputable reference in dentistry. Both morphology and occlusion are inseparable entities, thus ensuring all functions of the masticatory system, especially for posterior teeth. Therefore, careful attention must be paid to the occlusal morphology. A slightly higher occlusion would be immediately perceived by the patient with the practitioner removing premature contacts and interferences. Respecting the natural dentition and reproducing occlusal contacts is the hallmark of each successful restoration.¹ For direct resin restoration, respecting both morphology and occlusion relies heavily on the dentist's manual ability. However, for indirect restorations, it depends on the technician's ability, and should still be verified by the clinician. Today, milled restorations fabricated using an innovative tool called the biogeneric tooth model offer significant advantages. In 2010, Mehl and Blanz (2010)² developed this innovative tool. This approach involved analysing a collection of 170 intact first molars from children aged 6-9 years, approximately two years after eruption. Physical impressions were taken, and the resulting casts were scanned to create digital models. In a virtual environment, a single molar served as a

reference. The remaining images were then positioned in the same plane and orientation before being superimposed on the chosen reference. Well-defined reference points were used, and complex algorithms were employed to analyse the data. This process culminated in the creation of a mathematical representation of a tooth, known as the biogeneric model.

The present paper aimed to highlight the impact of biogeneric design by comparing the outcomes of two clinical situations treated with and without the biogeneric tool.

Clinical presentations

Case 1

A 32-year-old healthy female patient presented at the fixed prosthetics department of dental clinic of the Monastir Department. Her chief complaint was the restoration of her lower second molar (Fig. 1. A). Periapical radiograph showed inadequate canal filling (Fig. 1. B).

The tooth was asymptomatic and the patient declined the root canal retreatment. Thus, a lithium disilicate ceramic (IPS e.Max CAD) endocrown was indicated to avoid the canal preparation.

Once the tooth was prepared (Fig. 2), the master impression was taken and scanned. The virtual conception using in Lab®18.x software was performed. Then, the determination of both axes and limits, a tooth morphology was proposed arbitrarily and the occlusion

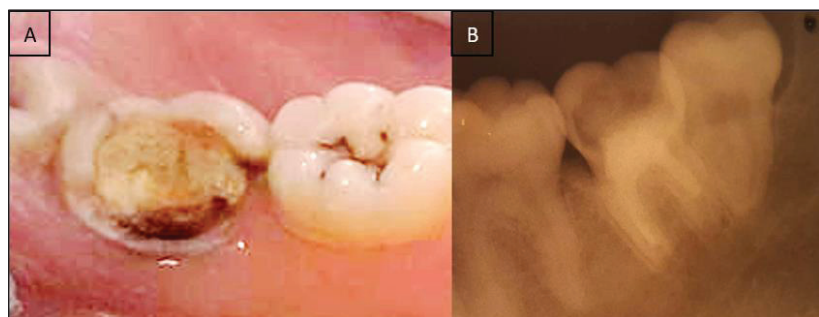


Fig. 1. Initial situation (A – occlusal aspect, B – periapical radiograph).

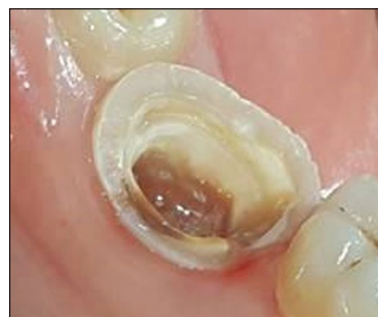

Fig. 2. After the tooth preparation.

was virtually checked (Fig. 3. A). Once the bonding procedure was conducted, occlusal adjustments were done. Finally, the endocrown exhibited flat and inappropriate morphology in comparison with the adjacent tooth (Fig. 3. B).

Case 2

A 27-year-old female patient, with noncontributory medical history, presented at the fixed prosthetics department of dental clinic of Monastir Department requesting an esthetic and functional rehabilitation of her upper first molar.

The clinical examination revealed that the problematic tooth was filled from both proximal sides (Fig. 4. A). The mesial surface was filled with resin material and the distal one was filled with amalgam material (Fig.

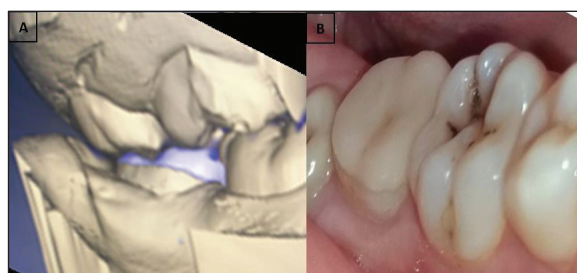


Fig. 3. Conception steps and the final aspect of the endocrown after occlusal adjustments (A – conception steps; B – the final aspect of the endocrown after the intra-oral checking of the occlusion).

4. B). Periapical radiograph showed adequate canal filling (Fig. 4. C). Once the fillings were removed, the occlusal area was almost totally destroyed. Thus, a lithium disilicate ceramic (IPS e.Max CAD) endocrown was the best therapeutic choice.

The preparation design of the endocrown was respected (Fig. 5) and the master impression was taken. The Exocad 3 ® software used the biogeneric tool to define the occlusal morphology of the restoration (Fig. 6). Once

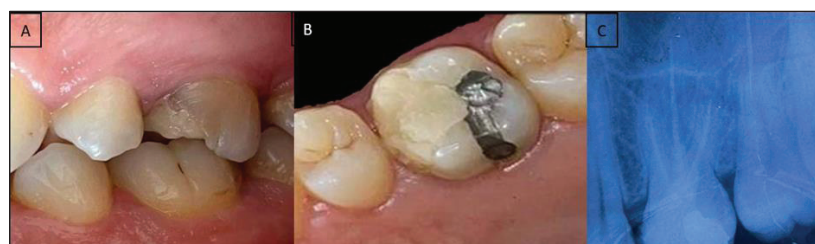


Fig. 4. Initial situation (A – buccal aspect, B – occlusal aspect, C – periapical radiograph).

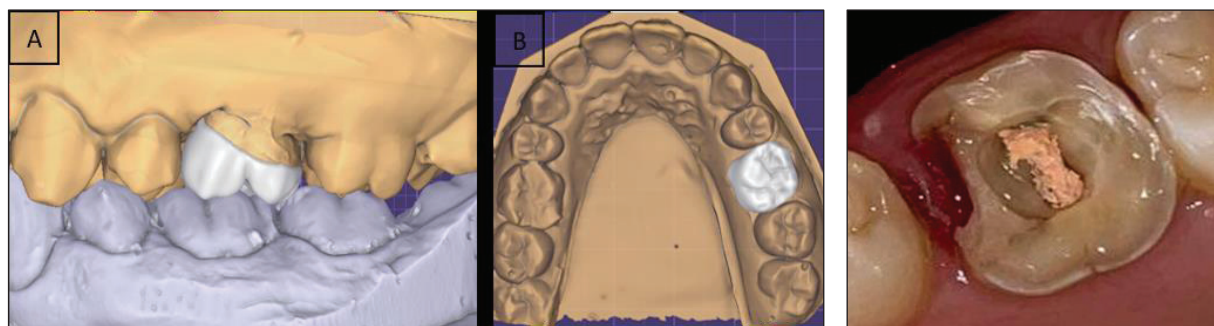


Fig. 5. Conception of the endocrown (A – buccal view, B – occlusal view). Fig. 6. After tooth preparation.

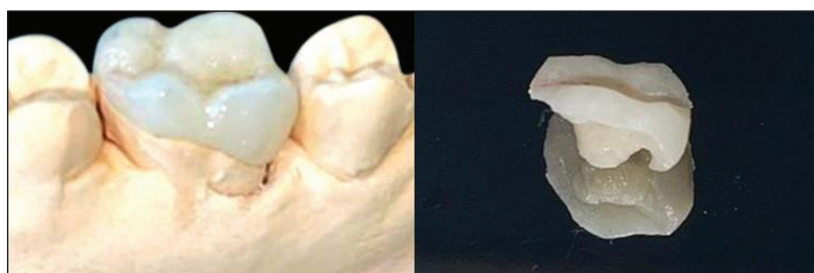

Fig. 7. Milled endocrown.

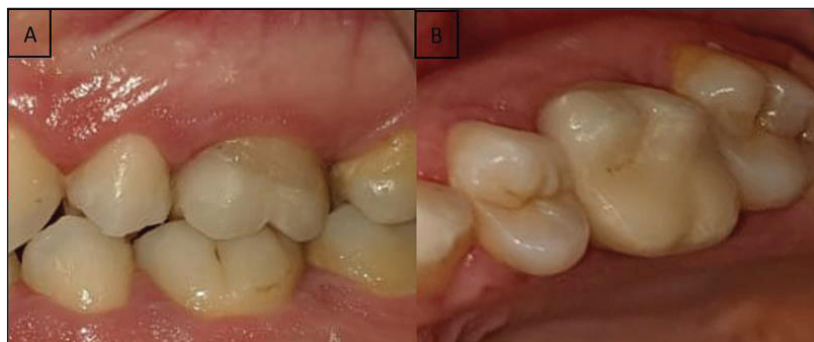

Fig. 8. Final outcome after occlusal adjustments with a respected morphology (A – buccal view, B – occlusal view).

milled (Fig. 7), it was checked intra-orally, then, carefully bonded. The occlusion control did not require much adjustments respecting the occlusal morphology (Fig. 8).

Discussion

For both clinical situations, the endocrown proves to be a suitable alternative for pulpless posterior teeth, aligning well with the concepts of bio-integration and therapeutic

gradient. The preparation is rational and straightforward, not involving the root canals.⁴ Studies have demonstrated the superior strength of endocrowns compared to conventionally crowned teeth with posts.⁵⁻⁷ These monolithic restorations, crafted from reinforced glass ceramics, exhibit a similar estimated survival rate to porcelain-fused-to-metal crowns. Therefore, the success and longevity of endocrowns primarily depend on the quality of bonding.^{3,6}

In the first presented clinical case, for the design of occlusal morphology, the software employed standard morphology.¹ Consequently, their intra-oral checking was time-consuming and required many individual adaptations and occlusal adjustments. Eventually, the restoration exhibited a flat morphology. In the second case, using the biogeneric tool, the occlusal morphology was respected even after the occlusion control.

The CEREC® v3.80 was the first software that allowed the reproduction of the entire original occlusal surface, even when it is completely lost.^{1,12} The CEREC® software includes three design modes: individual (BI), reference (BR), and copy (BC).¹³ The BI mode uses data from adjacent and opposing teeth. The BR mode creates a mirror image of the contralateral tooth, while the BC mode can copy the morphology of a selected tooth.^{12,13} In the described clinical situation, the BR mode was used because the homologue tooth was intact (Fig. 8). This tool is simple and automatic, allowing, in one click, the attainment of a natural morphology. It offers an individualized approach based on the natural dental model of each patient. Consequently, the milled piece presents both clinical and functional validity, avoiding the need for multiple grindings as performed for the first reported case.

Furthermore, its identical operating mode makes it suitable for various types of restorations such as crowns, endocrowns, veneers, inlays, onlays and monolithic bridges. This innovative technology has been the subject of various studies.^{8,13-16} Reich et al.¹⁷ found no significant difference between the morphology of CAD crowns and pressed all-ceramic crowns. Arslan et al.¹³ demonstrated a tooth morphology closely resembling the natural one. They reported that both BI and BR designs provided natural morphology in terms of cusp shape and fissure morphology. These findings were assessed by both postgraduate and undergraduate students.¹³

However, Fang Wang et al.¹⁴ concluded praising the superiority of the biogeneric copy mode compared to others.

Kollmuss et al.¹ conducted a study on the discrepancy between original tooth morphology, CAD reconstructions, wax-ups, and ceramic milled restorations. They found that differences associated with biogeneric reconstructions were significantly less than those of wax-ups, although not significantly different from those of milled restorations. Kollmuss also reported that the imprecision could be attributed to the bite registration. However, Ellerbrock¹⁸ reported contrary findings. On twelve posterior teeth, the biogeneric occlusal surfaces did not quite match the individually waxed ones mounted on the individually programmed articulator.

Certainly, the biogeneric tool ensures the respect of tooth morphology, enabling adequate occlusal contacts.¹⁹ Reich et al.,¹⁷ after comparing the original contact point patterns to those of CAD reconstruction, reported no statistically significant differences. However, milled crowns showed 87% agreement in contact patterns, while the pressed ones showed 95%. Additionally, Hartung¹⁶ studied contact pattern parameters such as number, size, and position. There was a high level of agreement between CAD reconstructions and milled crowns, reaching 78%, 76%, and 65% regarding the number, localization, and size and shape of the contact points.

Zhang et al.²⁰ conducted a comparison of the occlusion obtained from monolithic zirconia crowns designed by the biogeneric tool and the library method. They reported a better eccentric occlusion and reduced lateral occlusal interference. Arslan et al.¹³ investigated the occlusal contacts obtained with different biogeneric designs and established that the BI mode showed significantly better occlusion compared to the BC mode. According to Kollmuss et al.,¹⁵ Muric et al.,²¹ and Wang et al.¹⁴ most biogenically milled restorations

achieved the minimum number of occlusal contacts, ensuring mandibular stabilization. The systematic review by *Bohner* highlighted the evidence of the accuracy of digital methods concerning both morphology and occlusion.^{22,23}

The biogeneric tool has some limitations, mainly its relatively high cost.¹⁹ Furthermore, it is limited to monolithic restorations. *Muric et al.*²¹ reported the highest volume area discrepancy of wax up in comparison with natural design. This can be explained by the fact that the bridge has more volume and area details than the crowns or partial restorations. As always, long-term follow up is needed to ensure their overall success.¹⁴

Conclusion

When restoring posterior tooth, particular attention must be paid to occlusal morphology involving both harmonic intercuspation and the natural morphology. The biogeneric design is an innovative algorithm which describes mathematically the occlusal surfaces taking into account their natural variations. It ensures successful restorations with natural-like occlusal morphology alongside optimal occlusion. This is perfectly sought after, especially for minimally invasive restorations and in particular those of low thickness, thus preserving the properties of the materials.

References

1. *Kollmuss M, Jakob FM, Kirchner HG, Ilie N, Hickel R, Huth KC*: Comparison of biogenerically reconstructed and waxed-up complete occlusal surfaces with respect to the original tooth morphology. *Clin Oral Investig* 2013; 17(3): 851-857.
2. *Mehl A, Blanz V, Hickel R*: Biogeneric tooth: a new mathematical representation for tooth morphology in lower first molars. *Eur J Oral sci* 2005; 113(4): 333-340.
3. *Dogui H, Abdelmalek F, Amor A, Douki N*: Endocrown: An Alternative Approach for Restoring Endodontically Treated Molars with Large Coronal Destruction. *Case reports in dentistry*. 2018; 2018: 1581952.
4. *Fages M, Bennasar B*: The endocrown: a different type of all-ceramic reconstruction for molars. *J Can Dent Assoc* 2013; 79: d140.
5. *Biacchi GR, Basting RT*: Comparison of fracture strength of endocrowns and glass fiber post-retained conventional crowns. *Operative dentistry*. 2012; 37(2): 130-136.
6. *Sedrez-Porto JA, Rosa WL, da Silva AF, Münchow EA, Pereira-Cenci T*: Endocrown restorations: A systematic review and meta-analysis. *J Dent* 2016; 52: 8-14.
7. *Govare N, Contrepois M*: Endocrowns: A systematic review. *J Prosthet Dent* 2020; 123(3): 411-8.e9.
8. *Türp JC, Greene CS, Strub JR*: Dental occlusion: a critical reflection on past, present and future concepts. *J Oral Rehabil* 2008; 35(6): 446-453.
9. *Mehl A, Blanz V, Hickel R*: Biogeneric tooth: a new mathematical representation for tooth morphology in lower first molars. *Eur J Oral Sci* 2005; 113(4): 333-340.
10. *Dunn M*: Biogeneric and user-friendly: the Cerec 3D software upgrade V3.00. *Int J Comput Dent* 2007; 10(1): 109-117.
11. *Richter J, Mehl A*: Evaluation for the fully automatic inlay reconstruction by means of the biogeneric tooth model. *Int J Comput Dent* 2006; 9(2): 101-111.
12. *Ender A, Mörmann WH, Mehl A*: Efficiency of a mathematical model in generating CAD/CAM-partial crowns with natural tooth morphology. *Clin Oral Investig* 2011; 15(2): 283-289.
13. *Schenk O*: Biogeneric – another step closer to nature. V3.8: largest update since introduction of the 3D software. *Int J Comput Dent* 2010; 13(2): 169-174.
14. *Arslan Y, Karakoca Nemli S, Bankoğlu*

- Güngör M, Tamam E, Yılmaz H*: Evaluation of biogeneric design techniques with CEREC CAD/CAM system. *Journal Adv Prosthodont* 2015; 7(6): 431-436.
15. *Wang F, Tang Q, Xi S, Liu R, Niu L*: Comparison and evaluation of the morphology of crowns generated by biogeneric design technique with CEREC chairside system. *PloS one*. 2020; 15(1): e0227050.
16. *Kollmuss M, Kist S, Goeke JE, Hickel R, Huth KC*: Comparison of chairside and laboratory CAD/CAM to conventional produced all-ceramic crowns regarding morphology, occlusion, and aesthetics. *Clin Oral Investig* 2016; 20(4): 791-797.
17. *Hartung F, Kordass B*: Comparison of the contact surface pattern between virtual and milled Cerec 3D full-ceramic crowns. *Int J Comput Dent* 2006; 9(2): 129-136.
18. *Reich S, Brungsberg B, Teschner H, Frankenberger R*: The occlusal precision of laboratory versus CAD/CAM processed all-ceramic crowns. *Am J Dent* 2010; 23(1): 53-56.
19. *Ellerbrock C, Kordass B*: Comparison of Computer Generated Occlusal Surfaces with Functionally Waxed-on Surfaces. *Int J Comput Dent* 2011; 14(1): 23-31.
20. *Kallala R, Chaouch MH, Nasr K, Courset T*: Step-by-Step Esthetic Rehabilitation with Chairside System. *Case reports in dentistry*. 2021; 2021: 5558158.
21. *Zhang R, Ding Q, Sun Y, Zhang L, Xie Q*: Assessment of CAD-CAM zirconia crowns designed with 2 different methods: A self-controlled clinical trial. *J Prosthet Dent* 2018; 120(5): 686-692.
22. *Muric A, Gokcen Röhlig B, Ongul D, Evlioglu G*: Comparing the precision of reproducibility of computer-aided occlusal design to conventional methods. *J Prosthodont Res* 2019; 63(1): 110-114.
23. *Bohner LO, Neto PT, Ahmed AS, Mori M, Lagana DC, Sesma N*: CEREC Chairside System to Register and Design the Occlusion in Restorative Dentistry: A Systematic Literature Review. *J Esthet Restor Dent* 2016; 28(4): 208-220.

Zaakceptowano do druku: 2.07.2024 r.

Adres autorów: Dental Faculty of Medicine,
University of Monastir
LR16ES15, 5000, Monastir, Tunisia

© Zarząd Główny PTS 2024.