

Width-to-length ratio of maxillary anterior teeth in the diastematic dentition

Stosunek szerokości do długości przednich zębów szczęki w uzębieniu pacjentów z diastemą

Yosra Gassara¹, Rim Kallala², Mohamed Chebil¹, Sarra Nasri¹, Amani Adli¹, Zohra Nouria¹, Belhassen Harzallah¹, Mounir Cherif¹

¹ Department of Fixed Prosthodontics, Research Laboratory of Occlusodontics and Ceramic Prostheses
Faculty of Dental Medicine, University of Monastir, Monastir, Tunisia
Zakład Protetyki Stomatologicznej, Laboratorium Badawcze Okluzji Zębowej i Uzupełnień Ceramicznych,
Uniwersytet Monastyrski, Tunezja
Head: *Mounir Cherif*, PHD, Professor

² Department of Fixed Prosthodontics, Faculty of Dental Medicine, Monastir, Tunisia
Zakład Protetyki Stomatologicznej, Wydział Lekarsko-Dentystyczny, Uniwersytet Monastyrski, Tunezja
Head: *Mounir Cherif*, PHD, Professor

KEY WORDS:

diastema, dental, esthetics, incisor

HASŁA INDEKSOWE:

diastema, zębowy, estetyka, siekacz

Summary

Introduction. Diastema between maxillary anterior teeth may affect the smile, for that reason patients nowadays more and more often request a diastema closure procedure.

Aim of the study. To investigate the differences in the width-to-length ratio of maxillary anterior teeth in patients with and without diastema.

Material and methods. The study was conducted on Tunisian individuals (n=109) divided into two groups: the study group with diastema (n=50) and the control group without diastema (n=59). A digital vernier caliper was used to measure the length and width of maxillary anterior teeth on plaster models. The width was measured from mesial and distal contact points of the tooth on a line perpendicular to the long axis. The length measured the longest distance from the cervical margin to the incisal edge on a line parallel to the long axis. SPSS software was used to calculate the width-to-length ratio for each tooth and to analyze the data.

Results. Statistical analysis showed that there was no significant difference of width to length

Streszczenie

Wstęp. Diastema pomiędzy przednimi zębami w szczęce wpływa na estetykę uśmiechu, stąd też rośnie liczba pacjentów chcących się poddać zabiegowi jej zamknięcia.

Cel pracy. Sprawdzenie różnic w stosunku szerokości do długości przednich zębów w szczęce u pacjentów z diastemą lub bez niej.

Materiał i metody. Badanie przeprowadzono na populacji tunezyjskiej (n=109) dzieląc uczestników na dwie grupy: grupę badawczą z diastemą (n=50) i kontrolną bez diastemy (n=59). Posłużono się cyfrową suwmiarką do pomiaru długości i szerokości przednich zębów w szczęce na modelach gipsowych. Szerokość mierzono od mesialnych i dystalnych punktów styczności zęba w linii prostopadłej do długiej osi. Za długość przyjęto najdłuższą odległość od brzegu szyjki do brzegu siecznego w linii równoległej do długiej osi. Do obliczenia stosunku szerokości do długości dla każdego zęba i analizy danych użyto oprogramowania SPSS.

Wyniki. Analiza statystyczna wykazała brak istotnych różnic w stosunku szerokości do długości

ratio of maxillary anterior teeth in patients with or without diastema (left canine: $P=0.251$; left lateral incisor: $P=0.916$; left central incisor: $P=0.097$; right central incisor: $P=0.711$; right lateral incisor: $P=0.879$; right canine: $P=0.788$). The level of significance was set at 0.05.

Conclusions. The width-to-length ratio given in this study may serve as guidelines for treatment planning for the diastema closure procedure.

Introduction

Diastema is defined as a space greater than 0.5 mm between the proximal surfaces of two adjacent teeth. It has been attributed to several factors such as microdontia, labial frenulum, peg-shaped teeth, agenesis, dental-skeletal discrepancies, imperfect coalescence of the interdental septum, and also habits like thumb/finger sucking and tongue thrusting.^{1,2}

Diastema between maxillary anterior teeth may affect the smile and create disharmony in the patient's face, for which reason patients nowadays more and more often request to have their diastema closed.³⁻⁵

The esthetic treatment presents a challenge in clinical practice and should seek to manage not only the diastema in question but also the cause behind it. Thus a multidisciplinary approach including surgical correction, orthodontic closure, and restorative and prosthetic treatment may be required.⁶

The restorative closure of diastemata can be achieved by using direct or indirect composite veneers, partial veneers, porcelain laminate veneers, or all-ceramic crowns.

With these additive therapeutics, care must be taken not to over-contour the emergence profile which would create esthetic and hygiene problems with open gingival embrasure.⁵

In addition to that, the main objective of the clinician is to close the diastema without affecting the width-to-length ratio.²

ści przednich zębów w szczęce u pacjentów z diastemą lub bez (lewy kiel: $P=0.251$; lewy siekacz boczny: $P=0.916$; lewy siekacz przyśrodkowy: $P=0.097$; prawy siekacz przyśrodkowy: $P=0.711$; prawy siekacz boczny: $P=0.879$; prawy kiel: $P=0.788$). Za poziom istotności przyjęto 0.05.

Wniosek. Stosunek szerokości do długości ustalony w tym badaniu może służyć jako wyznacznik podczas planowania zabiegu zamknięcia diastemy.

Having large teeth may influence the patient's dentofacial harmony and esthetic appearance. So, in diastema cases, knowing the proportions of teeth is crucial for the treatment planning.

Preliminary studies on the dimensions of maxillary anterior teeth were done in the past only in a pilot group of patients. The present study has been conducted to investigate the differences in the width-to-length ratios of maxillary anterior teeth in patients with and without diastema.

Materials and methods

The study was conducted in the department of fixed prosthodontics on diagnostic prosthetic plaster models. All patients were Tunisians ($n = 109$) divided into two groups: the study group with diastema ($n = 50$) and the control group without diastema ($n = 59$).

The inclusion criteria were permanent dentition and aligned teeth.

The exclusion criteria included: evidence of gingival alterations or dental irregularities, loss of tooth structure due to attrition, fracture, caries or restorations, problems which affect the dentition and face, missing maxillary anterior teeth, periodontal diseases, maxillary anterior restorations, history of orthodontic treatment, patients with malocclusion and tooth disease.

Impression of the maxillary arch was taken using stock metal trays and irreversible

hydrocolloid; then poured immediately. During cast preparation, a mechanical vibrator was used to avoid air bubbles.

A digital vernier caliper was used to measure the height and width of maxillary anterior teeth on the plaster models.

The width was measured from the mesial to the distal contact point of the tooth on a line perpendicular to the long axis. The height measured the longest distance from the cervical margin to the incisal edge on a line parallel to the long axis.

To compare the dimensions of teeth, all measurements were tabulated in Microsoft Excel and statistical analysis was carried out using the Statistica 10 program. SPSS software was used to calculate the width-to-length ratio (%) for each tooth and to analyze the data.

Results

Female patients constituted the majority of the subjects (88.1% in the group with diastema and 74% in the group without diastema). The mean age in the study group was 24 years and in the control group 25 years.

Statistical analysis of the measurements of the width and length of investigated teeth showed that all the teeth in the study group had reduced dimensions compared to the teeth in the control group.

The comparison of widths of anterior teeth revealed significant differences for all the teeth except for the left lateral incisor and the right canine. The comparison of lengths of anterior teeth revealed significant differences for all the teeth except for the left lateral incisor (Table 1).

Table 1: The measurements of maxillary anterior teeth

Width	Group without diastema (mean±SD)	Group with diastema (mean±SD)	p*
Left canine	7.73±0.53	7.5±0.53	0.022
Left lateral incisor	6.7±0.66	6.48±0.56	0.052
Left central incisor	8.67±0.54	8.45±0.57	0.036
Right central incisor	8.8±0.58	8.47±0.55	0.004
Right lateral incisor	6.86±0.64	6.6±0.5	0.021
Right canine	7.87±0.5	7.68±0.52	0.053
Length			
Left canine	8.98±1	8.29±1.1	0.001
Left lateral incisor	7.97±0.9	7.66±1	0.09
Left central incisor	9.93±1	9.5±1	0.029
Right central incisor	9.9±1.1	9.3±1	0.008
Right lateral incisor	7.96±0.89	7.56±0.87	0.021
Right canine	8.87±1	8.22±1	0.002

Test applied: Student test; *p-value=0.05 (highly significant).

Table 2: The width- to- length ratios of maxillary anterior teeth

W/L RATIO	Group without diastema (mean±SD) mm	Group with diastema (mean±SD) mm	P*
Left canine	0.87±0.1	0.92±0.11	0,251
Left lateral incisor	0.85±0.1	0.86±0.11	0,916
Left central incisor	0.88±0.08	0.9±0.1	0,097
Right central incisor	0.9±0.1	1±0.1	0,711
Right lateral incisor	0.87±0.1	0.94±0.1	0,879
Right canine	0.9±0.1	0.94±0.09	0,788

Test applied: Student test; *p-value=0.05 (highly significant).

The result of this study showed that in the control group the Width-to-Length Ratio was 88% for the left central incisor, 90% for the right central incisor, 85% for the left lateral incisor, 87% for the right lateral incisor, 87% for the left canine and 90% for the right canine. In the group with diastema the Width-to-Length Ratio was 90% for the left central incisor, 100% for the right central incisor, 86% for the left lateral incisor, 94% for the right lateral incisor, 92% for the left canine and 94% for the right canine. Statistical analysis of the measurements of the dimensions of the investigated teeth showed that there was no significant difference of width-to-length ratio of maxillary anterior teeth in patients with diastema and in patients without diastema (Table 2).

Discussion

Diastema between maxillary anterior teeth is mainly caused by the discrepancy between teeth and maxilla dimension which can relate to two situations: first, when teeth have the correct size but the maxilla is too large, or second, when the maxillary bone has the proper size but teeth have reduced dimensions (microdontia).¹

The results of our research indicate that in the group of patients with diastema, the majority of teeth have reduced dimensions compared to teeth in the control group. These results are in accordance with those found in the *Sękowska* and *Chalas* study that revealed statistically significant differences in the length of central incisors and canines on both sides, and that all measurements of teeth proportions were lower in the diastema group.⁷

Several treatment modalities can be used for diastema closure. These include orthodontic treatment or restorative dentistry using such materials as ceramics or composite-based resins.⁸

When the morphology of the teeth and proportions are adequate, closing diastema using orthodontics may be achieved in many cases without the need for restorative dentistry. However, in some particular clinical cases with malshaped or discolored teeth, orthodontics by itself may not solve the esthetic problem; composite or prosthetic restorations may give an expected result.⁹

First, the diastema is measured, then that measurement is divided by two. The quotient is added to the existing width of each tooth, which gives an increased tooth width.

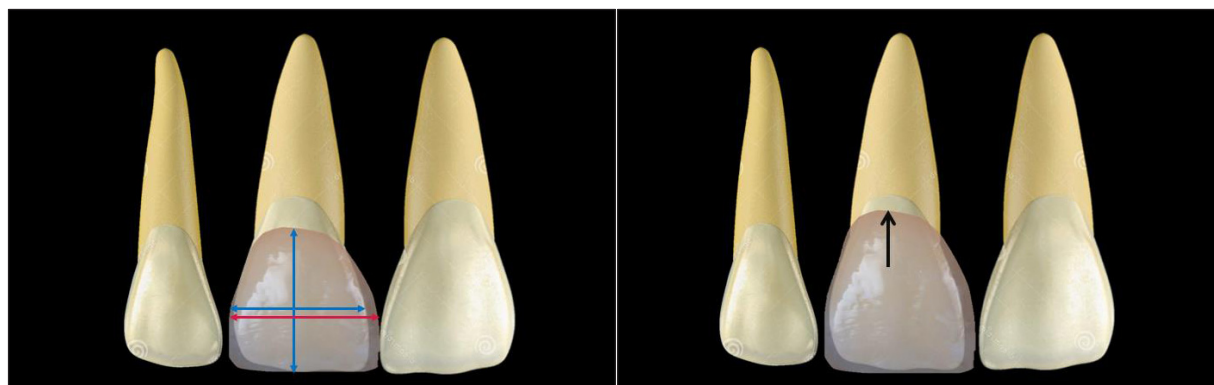


Fig. 1. Closure of diastema with ceramic veneers.

The measurement of teeth proportions of patients with anterior diastema is important in prosthetic treatment planning as any modification in the ideal width-to-length ratio may affect the patient's dentofacial harmony and the esthetic appearance.

In our study, it has been shown that diastema has no influence on the width-to-length ratio of anterior maxillary teeth.

Therefore, in cases with diastema where widening of teeth is required, lengthening of teeth should be planned to achieve the proper width-to-length ratio.

Several minimally invasive restorations have been described for diastema closure. The clinician should choose the most conservative modality, thereby avoiding unnecessary preparation of dental structure, while restoring function and aesthetic appearance. The evolution of minimally invasive dentistry was only possible thanks to technological development in ceramic systems and the advance of adhesive techniques.¹⁰

Some case reports described partial veneers for diastema closure, minimal tooth preparation may be required to remove proximal undercuts and create a horizontal insertion axis for the veneer. However, with this type of restoration, the length of the teeth cannot be increased, which could lead to large teeth.¹⁰

The "no-prep" veneers were indicated for

certain types of problems concerning the size and shape of the teeth. In the case of diastema with microdontia, this alternative can offer an esthetic result while preserving the dental tissue since the dental structure allows material to be added without modifying or creating an overcontour.¹¹

Before initiating prosthetic treatment, it would be beneficial to carry out an esthetic and digital analysis through efficient corresponding software to avoid tooth size discrepancy and to maintain the proper measurements of the width, length, and width-to-length proportion of maxillary anterior teeth (Figure 1). Digital Smile Design software may help the clinician to visualize the prosthetic project and decide about the appropriate treatment.¹²

In addition, a plaster model with diagnostic wax (wax-up) should be performed, and an oral simulation using composite materials (mock-up) should be tested. After accepting the shape and proportion of the teeth, the restoration can be made.

The increase in the length of the teeth can be achieved at the expense of the incisal edge if the occlusion allows it (open bite), or in some situations a minimally invasive surgery for clinical crown lengthening is necessary to have an esthetic result with a harmonious width-to-length ratio.

Also, clinician could change the tooth

dimension by modifying the placement of the labial transitional line angle, which is called illusion phenomenon. This feature could significantly influence the visual perception of the teeth and smile. Authors consider that the tooth's perceived dimensions are those measured between mesial and distal labial transitional lines angles and called "esthetic width" or "virtual width". Plate surface gives optical width increase and rounded surface produces a reduced width, which can hide a slight disharmony of tooth dimension.^{13,14}

Finally, the ideal treatment for diastema closure should be determined upon a diagnostic evaluation of the diastema size, length, and proportion of the clinical crowns, the occlusion, and the anterior guidance.

Conclusions

Taking into account the limitations of this study, the following conclusions were made: along with other objective parameters related to dental esthetics, the width-to-length ratio given in this study may serve as guidelines for treatment planning for diastema closure. In the group of patients with diastemata, teeth have reduced dimensions compared to teeth in the control group. Finally, there is no influence of diastema on the width-to-length ratio of anterior maxillary teeth.

References

1. *Sindhu Saeralaathan, Vamsi Lavu, Mathan Rajan, SK Balaji, Arathi Ganesh*: An interdisciplinary approach to management of diastemas: A novel classification and a case report; *Indian J Dent Res* 2021; 32(2): 250-255.
2. *Naorongroj S*: Esthetic Reconstruction of Diastema with Adhesive Tooth-Colored Restorations and Hyaluronic Acid Fillers. *Case Rep Dent* 2017; 2017: 5670582.
3. *Sedat Guven, Tahir Karaman, Mehmet Unal, Ihsan Cemal Melek*: Rehabilitation of open bite with diastema using zirconia ceramic crowns: case report. *J Int Dent Med Res* 2013; 6(2): 88-91.
4. *Yosra Gassara, Nouha Hassine, Dalenda Hadyaoui*: Porcelain veneers versus full coverage crowns, *Scholars' Press*, 2019.
5. *Umar Hussaina, Ali Ayubb, Muhammad Farhanc*: Etiology and treatment of midline diastema: A review of literature. *POJ* 2013; 5(1): 27-33.
6. *Deepak Thomas, Krishnan Hari, Joy Mathew, Sajeev Bhaskaran*: Esthetic Correction with Laminate Veneers. A Case Series. *RRJDS, Aesthetic Restorations - S1*, 2017; 21-26.
7. *Sękowska A, Chalas R*: An odontometric study of tooth dimension in diastematic dentition; *Folia Morphol* 2020; 79(3): 604-609.
8. *Kumar A, Shetty RM, Dixit U, Mallikarjun K, Kohli A*: Orthodontic Management of Midline Diastema in Mixed Dentition. *Int J Clin Pediatr Dent* 2011; 4(1): 59-63. doi: 10.5005/jp-journals-10005-1083
9. *Gerardo Durán, Francisca Vivar, José Tisi, Ismael Henríquez*: The use of direct composite resin to close maxillary midline diastema complementary to orthodontic treatment. *Rev Clin Periodoncia Implantol Rehabil Oral* 2019; 12(2): 106-108.
10. *Arcelino Farias-Neto, Edna Maria da Cunha Ferreira Gomes, Alfonso Sánchez-Ayala, Alejandro Sánchez-Ayala, Larissa Soares Reis Vilanova*: Esthetic Rehabilitation of the Smile with No-Prep Porcelain Laminates and Partial Veneers. *Case Rep Dent* 2015; 2015: 452765.
11. *Dominiak H, Śmielak B*: Use of porcelain veneers without preparation ("no-prep") to change the shape of conical teeth – case report; *Prosthodontics* 2020; 70(3): 313-320.
12. *Celia Regina Maio Pinzan-Vercelino, Caroline Chavier Pereira, Lucyneide Rocha Lima, Julio Araujo Gurgel, Fausto Silva Bramante*,

- Alex Luiz Pozzobon Pereira, Darlon Martins Lima, Matheus Coelho Bandeca: Two-Year Follow-up of Multidisciplinary Treatment Using Digital Smile Design as a Planning Tool for Esthetic Restorations on Maxillary Midline Diastema. Int J Orthod Milwaukee 2017; 28(1): 67-70.*
13. *Gallucci GO, Guex P, Vinci D, Belser UC: Achieving natural-looking morphology and surface textures in anterior ceramic fixed rehabilitations. Inter J Periodontics & Res Dent 2007; 27(2): 117-125.*
14. *Rim Kallala, Yosra Gassara, Ines Azouzi, Amani Adli, Dalenda Hadyaoui, Zohra Nouira, Chiraz Baccouche, Soumaya Touzi, Belhassen Harzallah, Mounir Cherif: Facial Line Angles: A Key to Tooth-like Rehabilitation; Case Reports in Dentistry 2022, Article ID 4917536, 5 pages.*

Zaakceptowano do druku: 11.02.2023 r.

Adres autorów: Monastir, Tunisia,
Street of genev-Skanes- Monastir,
5000, Monastir, Tunisia

© Zarząd Główny PTS 2023.

Acknowledgements

The authors of this study would like to thank their colleagues from the department of fixed prosthodontic who provided insight and expertise that greatly assisted the research.